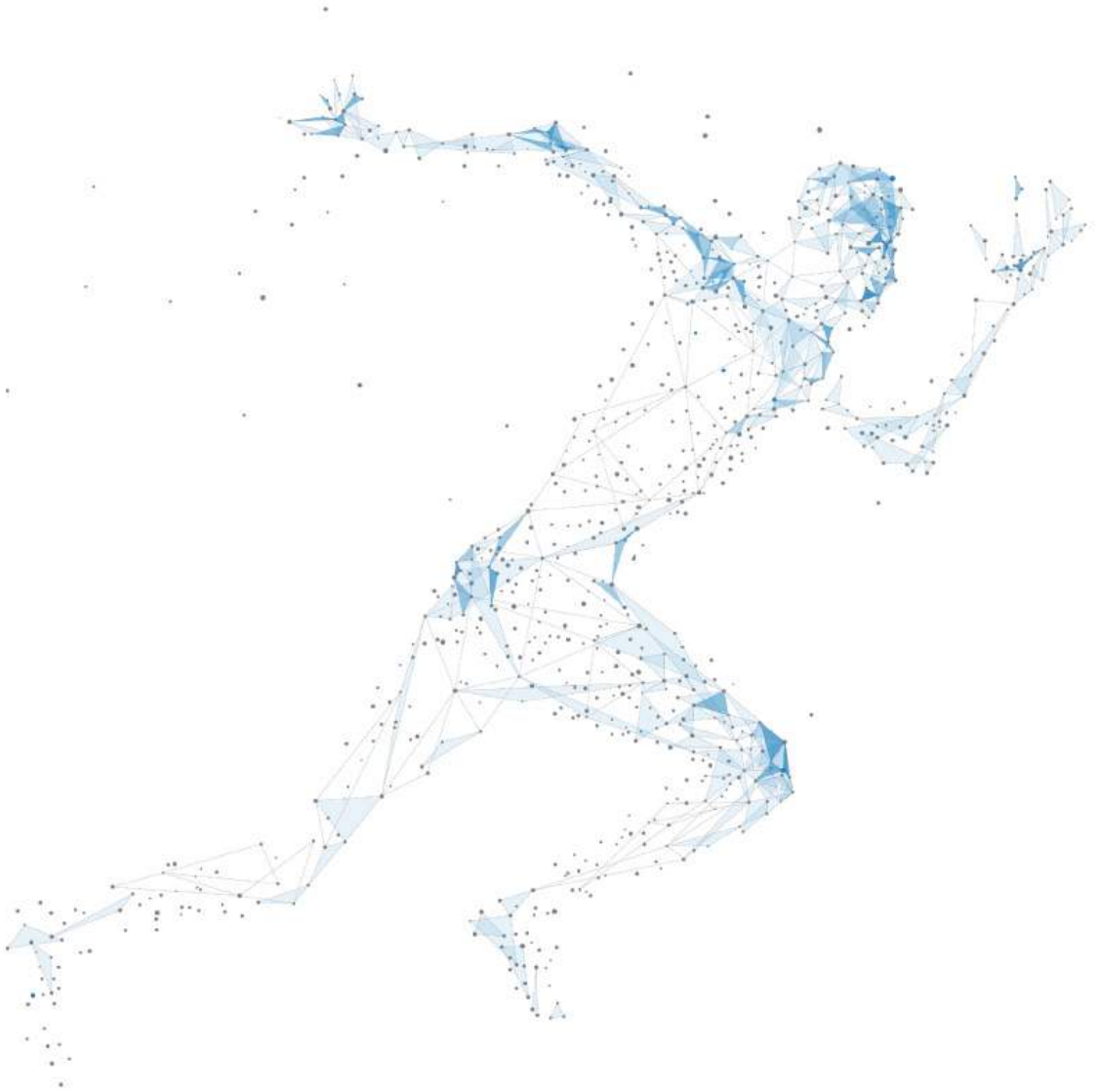




**SPECTRUM**  
DYNAMICS MEDICAL



## SPECT/CT Imaging Bone Infection

Dynamic, Blood Pool and Delayed Bone / Leukocyte imaging on the VERITON-CT® digital SPECT/CT

Submitted by Dr Sergio Lafuente Carrasco and Dr Glòria Moragas Freixa. Data and images courtesy of Hospital Universitario Germans Trias i Pujol, Barcelona, Spain.  
May 2023.

[www.spectrum-dynamics.com](http://www.spectrum-dynamics.com)

### CASE Three Phase Bone:

54-year-old male smoker (40 yrs x 1 pack/day); no known drug allergies; alcohol and toxin free.

Sensory-motor polyneuropathy with severe axonal loss in the lower extremities. Demyelinating features in the upper extremities. Signs of acute denervation of slow onset (4 years) attributed to diabetic origin. Progressive loss of independence due to the polyneuropathy with marked lower limb weakness since 2017. Walks with the aid of a cane and at home mobility is limited to bed-chair transfers; dependent on a motorised chair when leaving home. Higher functions are preserved.

### Clinical Scan:

**VERITON-CT 264** three phase bone scan with labelled leucocytes. Rule out osteomyelitis infection of the left foot in diabetic patient with sensory-motor polyneuropathy.

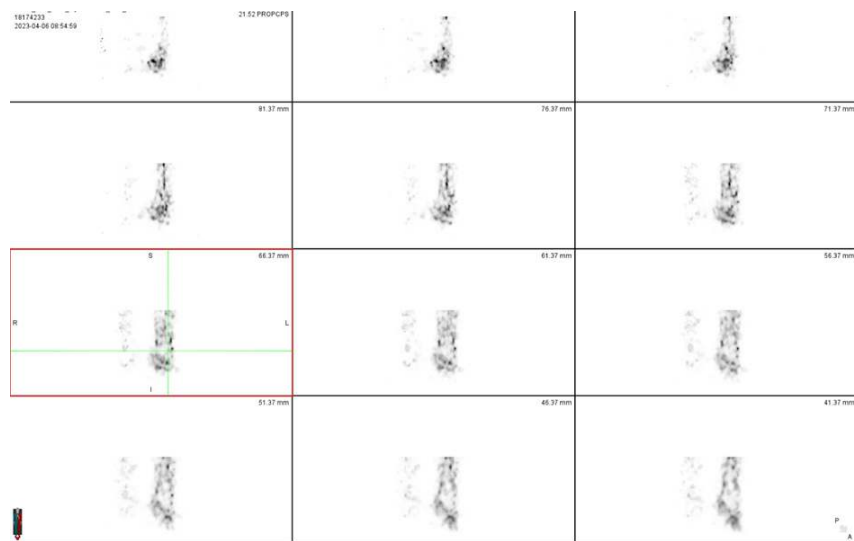
Radiotracer and Dose:

### Three Phase Bone scan:

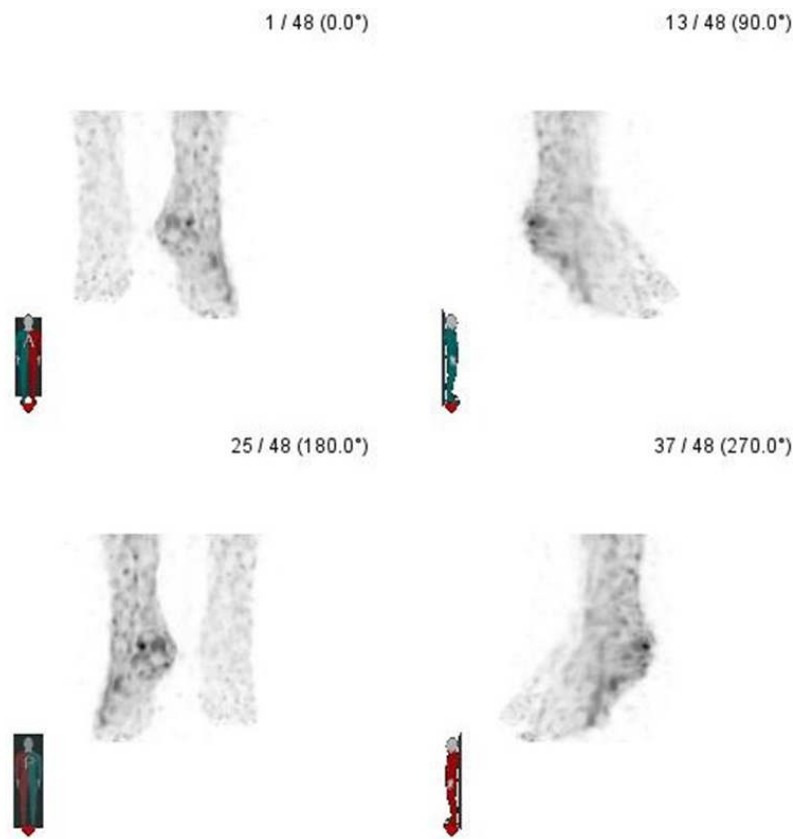
- Radiopharmaceutical: 99mTc-HMDP
- Dose: adults 18-25 mCi (740-925 MBq)

### Labelled Leucocyte scan:

- 14 mCi 99Tcm SCINTIMUN (HAMAS test negative)



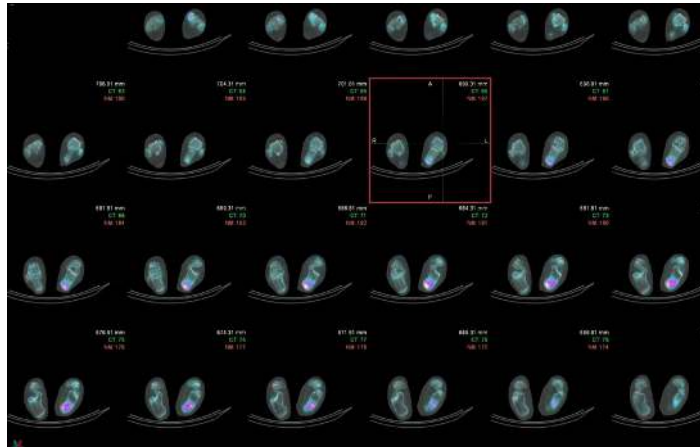
IMG 1: Flow phase demonstrates increased vascularity of the left foot.



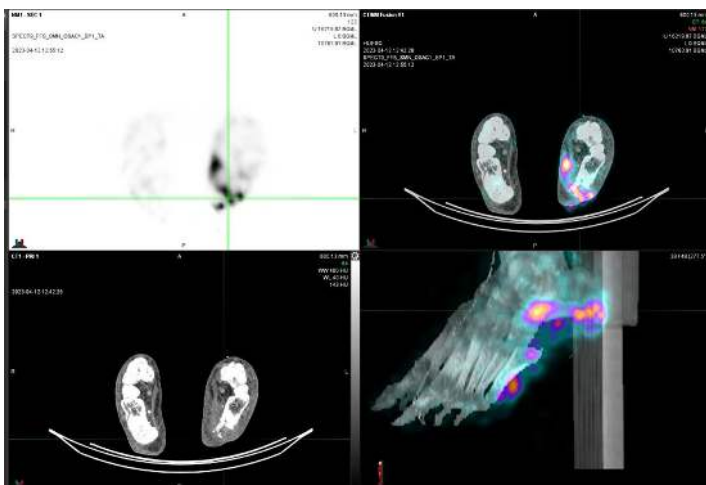
IMG 2: Blood pool phase demonstrates increased vascularity concentrated within the left heel region and on the external surface of the left foot.



**SPECTRUM**  
DYNAMICS MEDICAL



IMG 3: Delayed bone scan phase demonstrates increased bone uptake within the left calcaneus and the left 5th metatarsus.

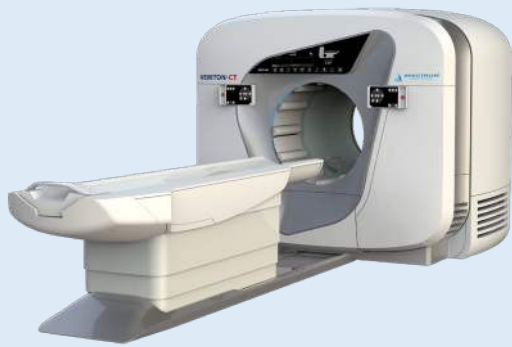

IMG 4: Labelled leucocyte scan demonstrates pathological uptake of leukocytes in the left calcaneus and head of the left 5th metatarsus, which correlates with the bone scintigraphy findings, however no uptake is observed at the base of the 5th metatarsus.

**Findings:**

Increased vascularization of the left foot, especially in the area of the calcaneus and external surface, in both the dynamic images and the early 10-minute blood pool images.

These findings are suggestive of osteomyelitis of the left calcaneus, with involvement of soft tissue and the head of the 5th metatarsal bone.



**VERITON-CT  
Technology**

Spectrum Dynamics Medical built the VERITON-CT with a new generation imaging technology like no other, wrapping 360° around the body's contour for a personalized exam. The heart of the innovation is Spectrum's proprietary Broadview Technology: a set of 12 digital CZT detectors that automatically move within millimeters of the patient's body.

The scanner was designed with the patient's comfort in mind. The axial field of view, 32 cm, ensures organs such as lungs are imaged in one bed position scan. The 80 cm bore, for both SPECT and CT, accommodates patients of all sizes. For patients worried about feeling a sense of claustrophobia, the detectors will automatically pull back if they are accidentally or intentionally touched.

Clinicians can use the high-resolution, 16sl or 64sl, CT scan data not only for attenuation correction and localization, but also to routinely reconstruct SPECT data with partial volume correction (PVC) for improved contrast and resolution. The 3D hybrid digital scanner gives clinicians comprehensive information to help diagnose with confidence and accuracy.





The Germans Trias i Pujol University Hospital is a public health center located at the foot of the Sierra de la Marina, in the municipality of Badalona, close to Barcelona. It is built on municipally owned land, which was formerly a farm called Can Ruti, the name by which the hospital is popularly known. The official name of the hospital was given to honour the memory of two brothers from Badalona, surgeons and professors: Joaquim Trias i Pujol (1888-1964) and Antoni Trias i Pujol (1892-1970).

The hospital focusses in two main areas: research, through the Science Research Institute of Salut Germans Trias I Pujol; and teaching, with courses in a number of Health Studies disciplines at both undergraduate and postgraduate levels and a collaboration agreement with the Autonomous University of Barcelona.

Since first coming into operation, the hospital has grown considerably and undergone numerous extensions of the services provided. Currently Germans Trias I Pujol Hospital is one of the largest reference hospitals in the country.

Currently, diagnostic procedures are performed within a collaborative medical imaging service environment that incorporates both anatomical and molecular imaging procedures. Thus, in recent years, there has been much greater interest and investment in hybrid imaging systems and studies of Nuclear Medicine, Computerized Tomography (SPECT CT) and soon PET/CT, for use across multiple fields of clinical practice, including oncology, cardiology and endocrinology, amongst other specialities.

[www.hospitalgermanstrias.cat](http://www.hospitalgermanstrias.cat)



Germans Trias Nuclear Medicine Team Photo

Dr. Glòria Moragas Freixa is Head of the Department of Nuclear Medicine at the Germans Trias i Pujol University Hospital.

Dr. Sergio Lafuente Carrasco is a Nuclear Medicine physician.



Dr Sergio Lafuente Carrasco



**SPECTRUM**  
DYNAMICS MEDICAL

Salut/



**Germans Trias i Pujol**  
Hospital



Generalitat  
de Catalunya